県北にもステントグラフト治療を

津山中央病院　心臓血管外科
久保陽司

本邦における過去10年間の心臓大血管手術数の推移

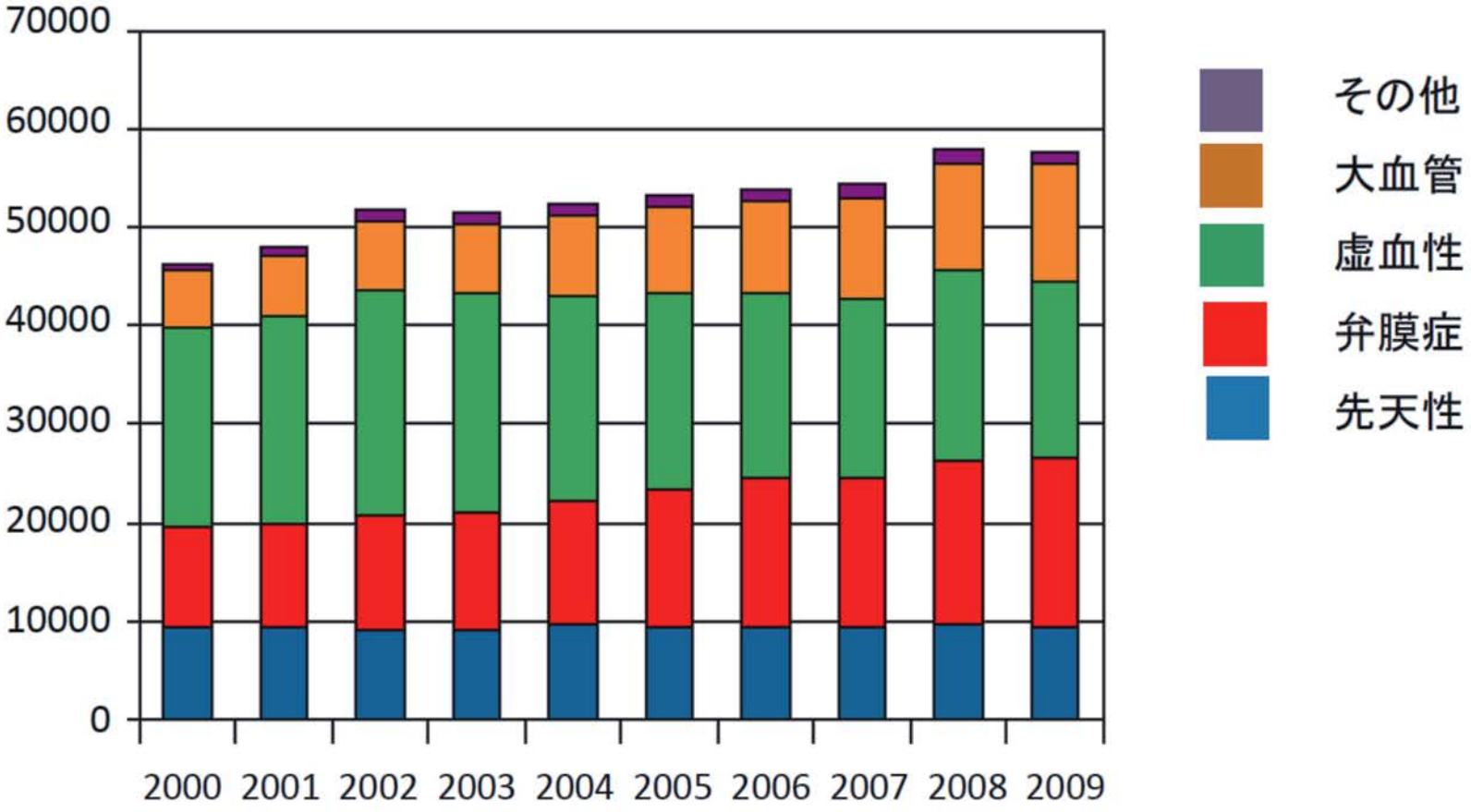

血管内治療の導入

冠動脈バイパス

➢ 経皮的冠動脈形成術（PCI）

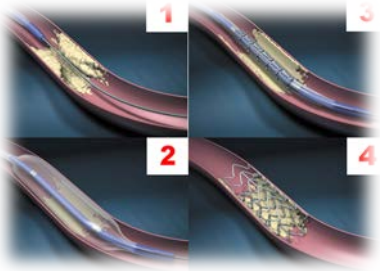

不整脈手術

➢ カテーテルアブレーション



大動脈瘤人工血管置換

➢ ステントグラフト内挿術

大動脈弁置換

➢ 経皮的大動脈弁置換（TAVI）

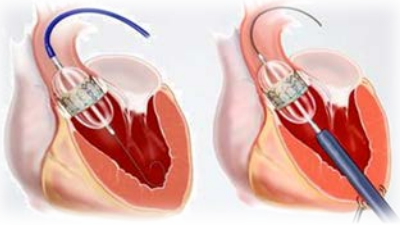

今日のおはなし

- ✓ ステントグラフトとは？
- ✓ 腹部大動脈瘤のステントグラフト治療
- ✓ 胸部大動脈瘤のステントグラフト治療
- ✓ 症例提示

ステントグラフトの登場

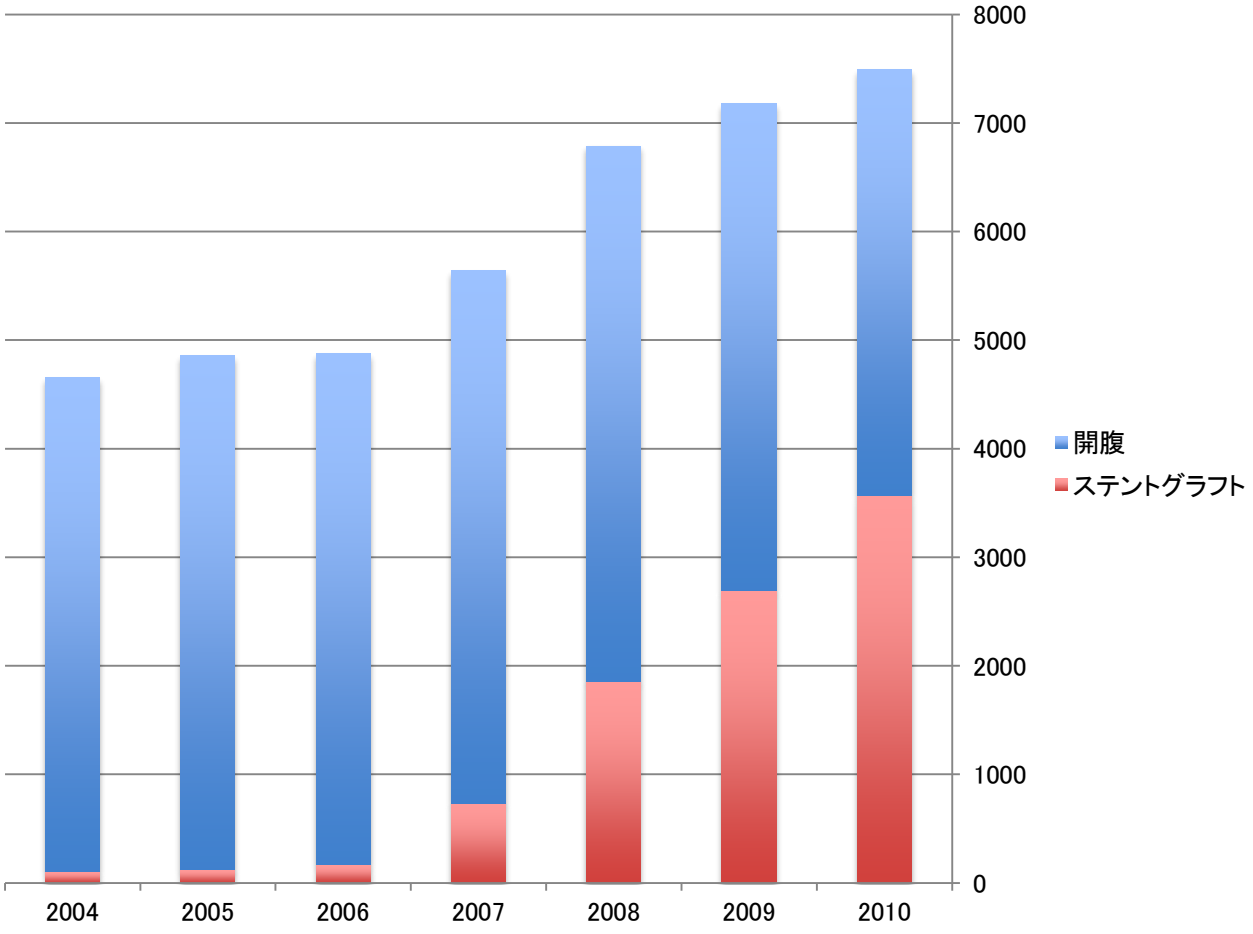

世界ではじめてのステントグラフト

パロディ 先生（Juan Carlos Parodi）

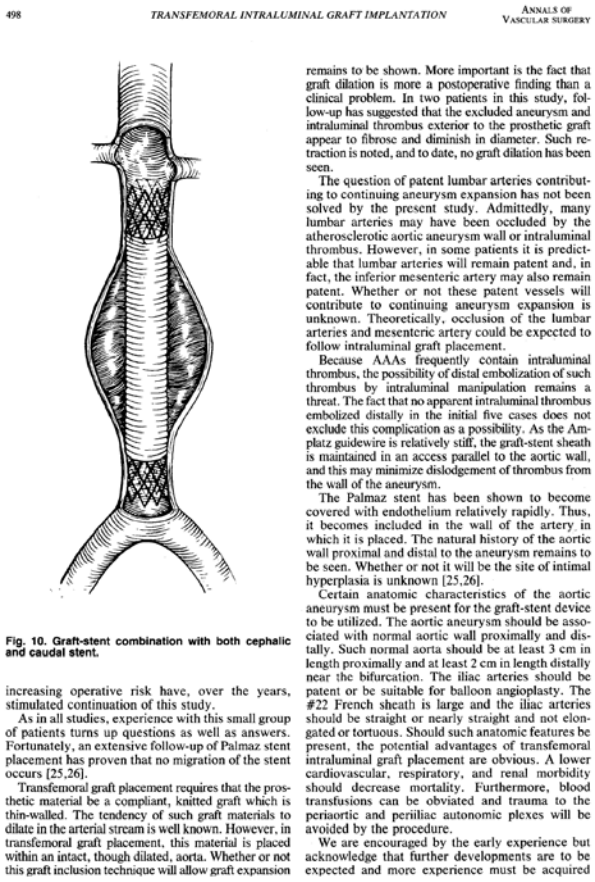

498 TRANSFEMORAL INTRALUMINAL GRAFT IMPLANTATION ANNALS OF VASCULAR SURGERY

Fig. 10. Graft-stent combination with both cephalic and caudal stent.

increasing operative risk have, over the years, stimulated continuation of this study.

As in all studies, experience with this small group of patients turns up questions as well as answers. Fortunately, an extensive follow-up of Palmaz stent placement has proven that no migration of the stent occurs [25,26].

Transfemoral graft placement requires that the prosthetic material be a compliant, knitted graft which is thin-walled. The tendency of such graft materials to dilate in the arterial stream is well known. However, in transfemoral graft placement, this material is placed within an intact, though dilated, aorta. Whether or not this graft inclusion technique will allow graft expansion remains to be shown. More important is the fact that graft dilation is more a postoperative finding than a clinical problem. In two patients in this study, follow-up has suggested that the excluded aneurysm and intraluminal thrombus exterior to the prosthetic graft appear to fibrose and diminish in diameter. Such retraction is noted, and to date, no graft dilation has been seen.

The question of patent lumbar arteries contributing to continuing aneurysm expansion has not been solved by the present study. Admittedly, many lumbar arteries may have been occluded by the atherosclerotic aortic aneurysm wall or intraluminal thrombus. However, in some patients it is predictable that lumbar arteries will remain patent and, in fact, the inferior mesenteric artery may also remain patent. Whether or not these patent vessels will contribute to continuing aneurysm expansion is unknown. Theoretically, occlusion of the lumbar arteries and mesenteric artery could be expected to follow intraluminal graft placement.

Because AAAs frequently contain intraluminal thrombus, the possibility of distal embolization of such thrombus by intraluminal manipulation remains a threat. The fact that no apparent intraluminal thrombus embolized distally in the initial five cases does not exclude this complication as a possibility. As the Amplatz guidewire is relatively stiff, the graft-stent sheath is maintained in an access parallel to the aortic wall, and this may minimize dislodgement of thrombus from the wall of the aneurysm.

The Palmaz stent has been shown to become covered with endothelium relatively rapidly. Thus, it becomes included in the wall of the artery in which it is placed. The natural history of the aortic wall proximal and distal to the aneurysm remains to be seen. Whether or not it will be the site of intimal hyperplasia is unknown [25,26].

Certain anatomic characteristics of the aortic aneurysm must be present for the graft-stent device to be utilized. The aortic aneurysm should be associated with normal aortic wall proximally and distally. Such normal aorta should be at least 3 cm in length proximally and at least 2 cm in length distally near the bifurcation. The iliac arteries should be patent or be suitable for balloon angioplasty. The #22 French sheath is large and the iliac arteries should be straight or nearly straight and not elongated or tortuous. Should such anatomic features be present, the potential advantages of transfemoral intraluminal graft placement are obvious. A lower cardiovascular, respiratory, and renal morbidity should decrease mortality. Furthermore, blood transfusions can be obviated and trauma to the periaortic and periiliac autonomic plexes will be avoided by the procedure.

We are encouraged by the early experience but acknowledge that further developments are to be expected and more experience must be acquired

1991年に発表

ステントグラフトとは



＋

＝

ステント　　グラフト

人工血管を“縫い付ける”かわりに

ステントで“圧着”する

ステントグラフト治療とは

「正常な血管から正常な血管へのバイパス手術」

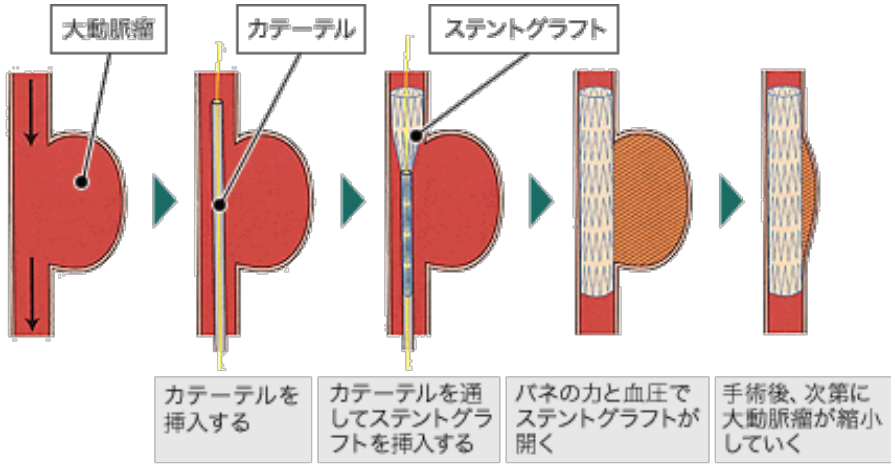

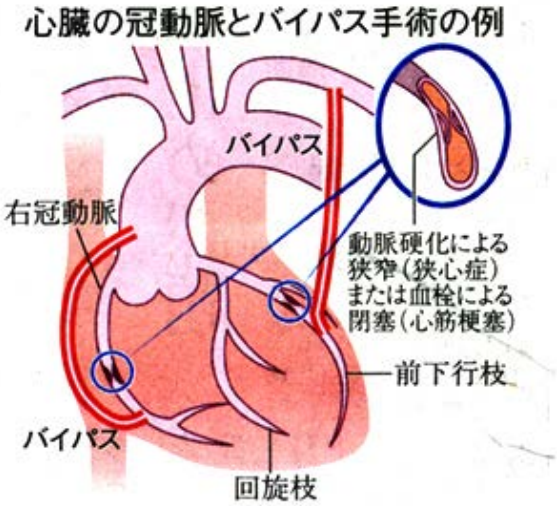

動脈瘤をバイパスする

今日のおはなし

- ✓ ステントグラフトとは？
- ✓ 腹部大動脈瘤のステントグラフト治療
- ✓ 胸部大動脈瘤のステントグラフト治療
- ✓ 症例提示

腹部大動脈瘤の治療

EVAR = EndoVascular Aneurysm Repair

Zenith

Excluder

ENDURANT

IntuiTrak

EVARの成績

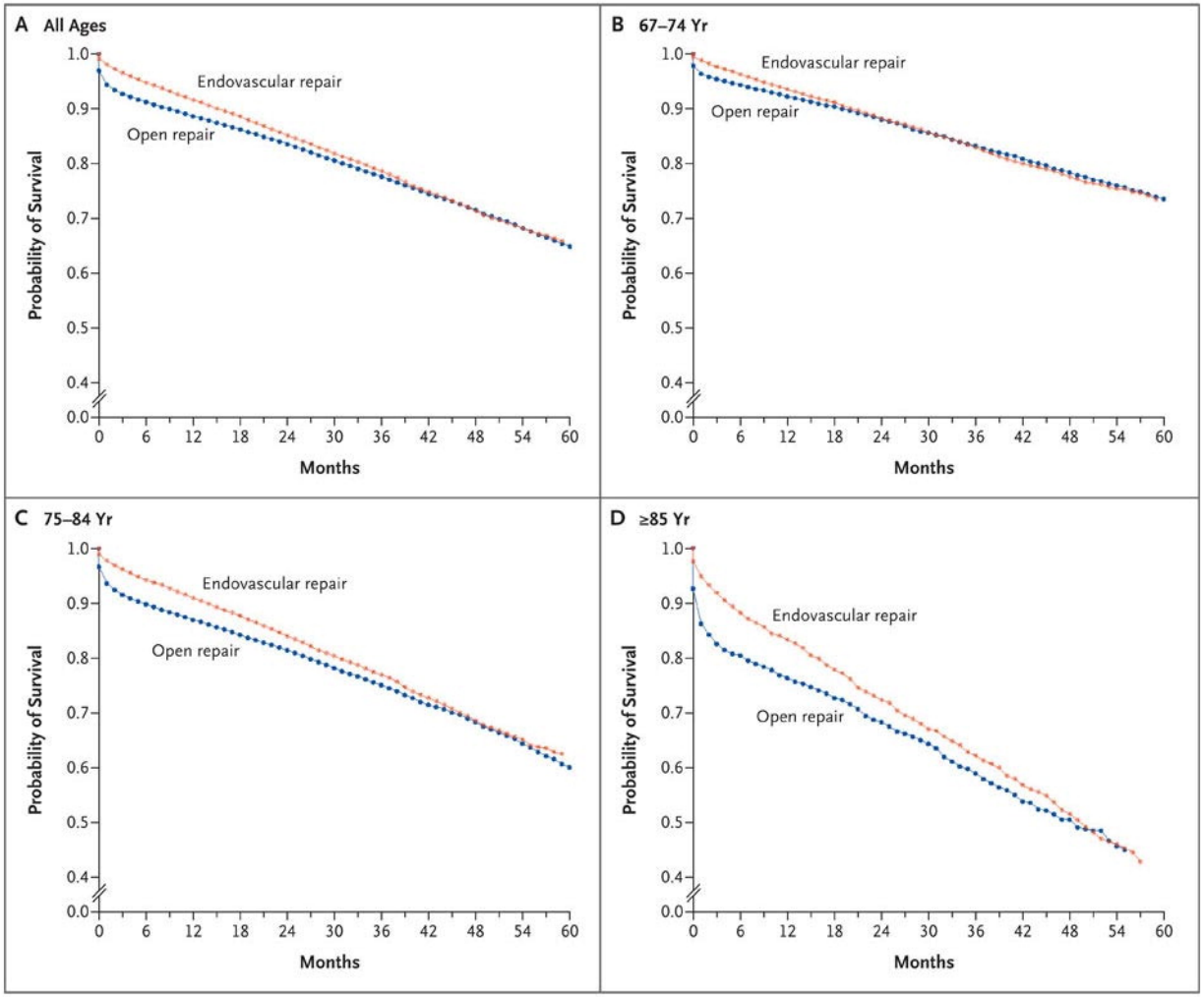

N Engl J Med 2008; 358: 464-474

エンドリーク

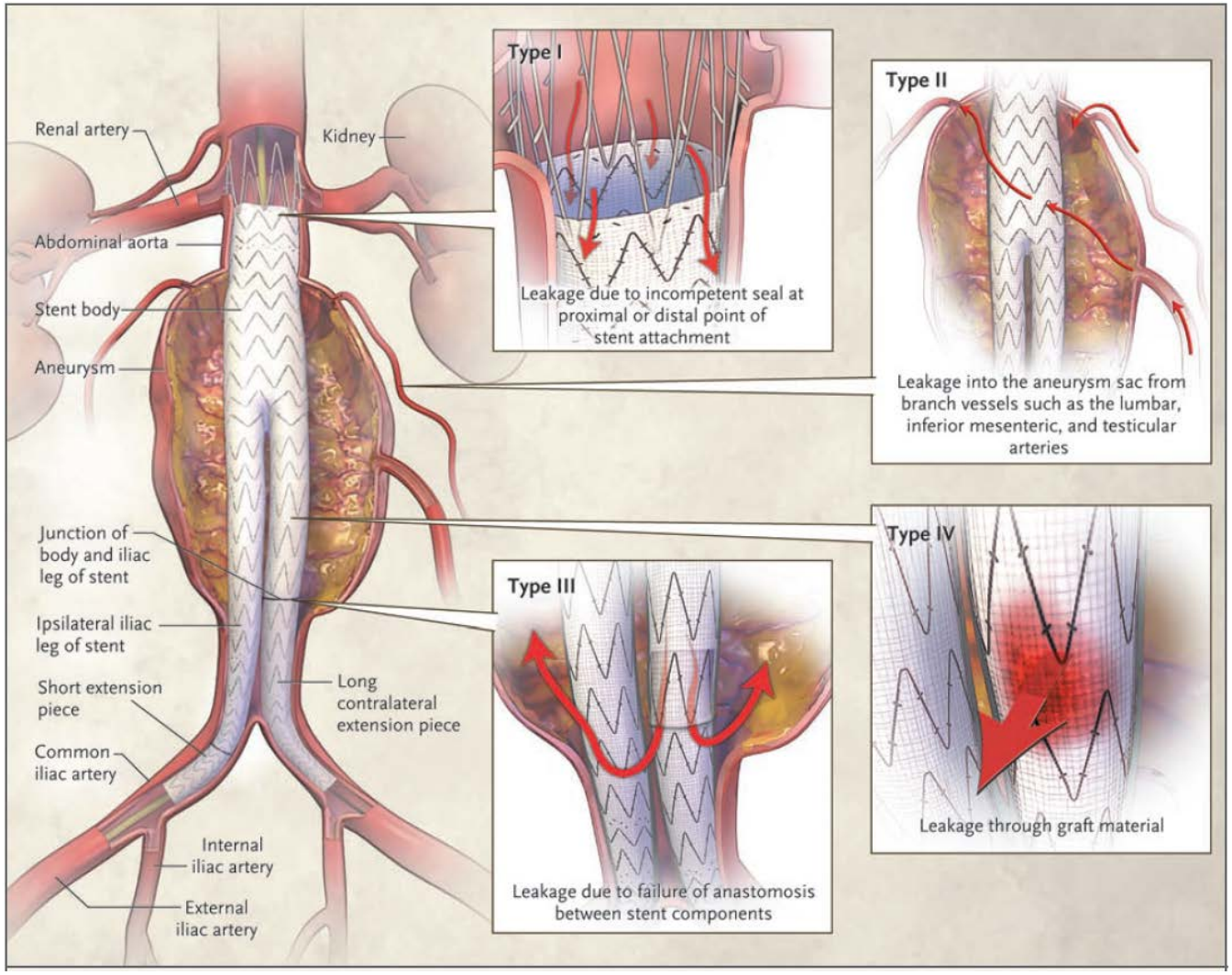

N Engl J Med 2008 ; 358:494-501

今日のおはなし

- ✓ ステントグラフトとは？
- ✓ 腹部大動脈瘤のステントグラフト治療
- ✓ 胸部大動脈瘤のステントグラフト治療
- ✓ 症例提示

胸部大動脈瘤の治療

TEVAR = Thoracic EndoVascular Aneurysm Repair

TX2

TAG

VALIANT



RELAY

腹部にくらべると…

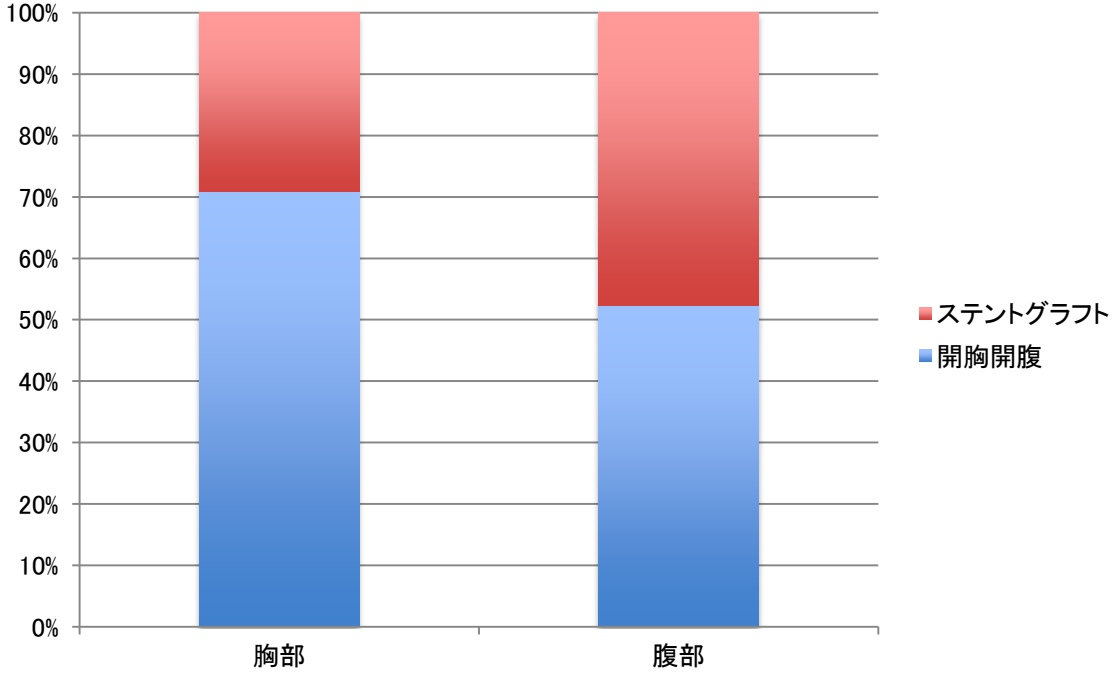

30%　　50%

TEVARのうちわけ

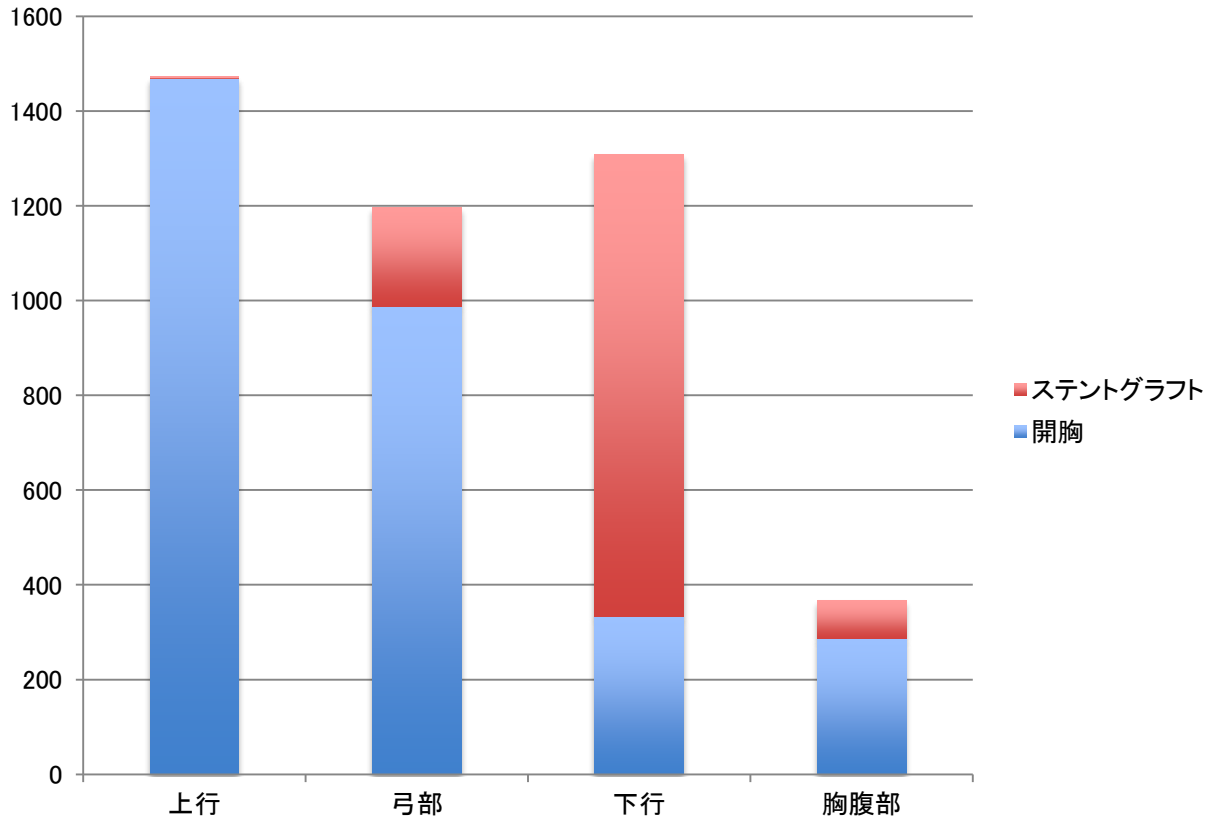

胸部 ～ 胸腹部大動脈瘤の特徴

「重要な分枝血管が近い！」

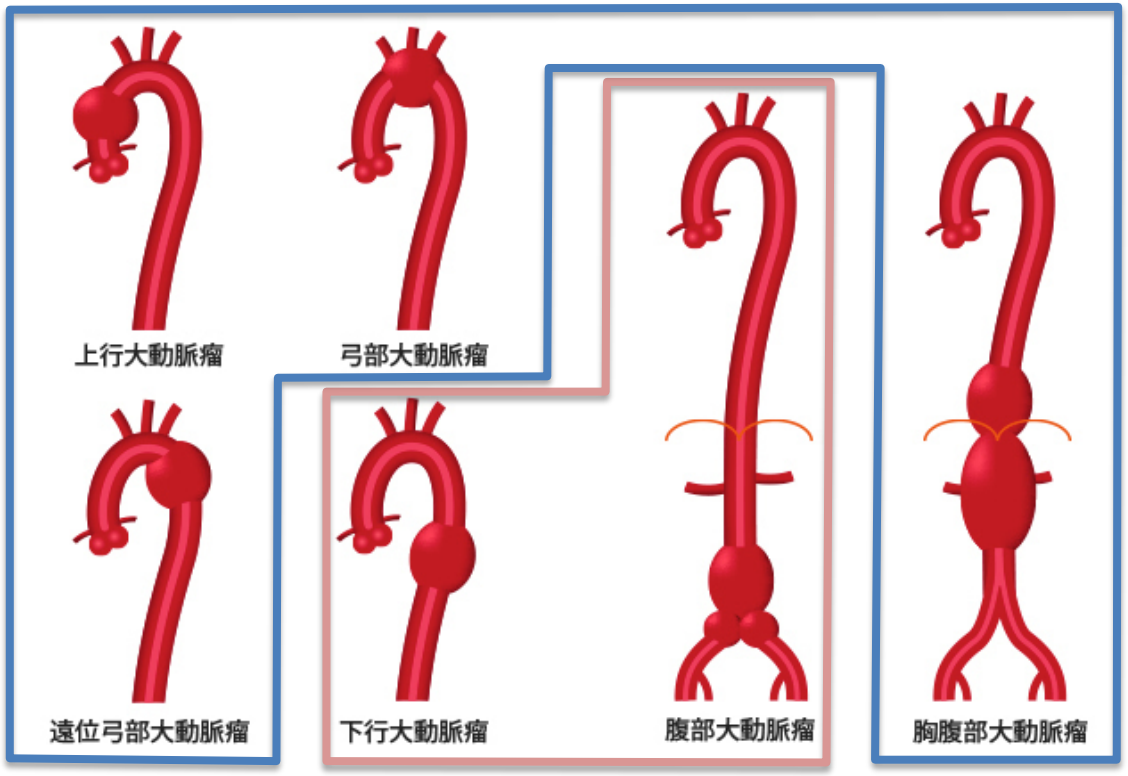

EVARにおける重要分枝

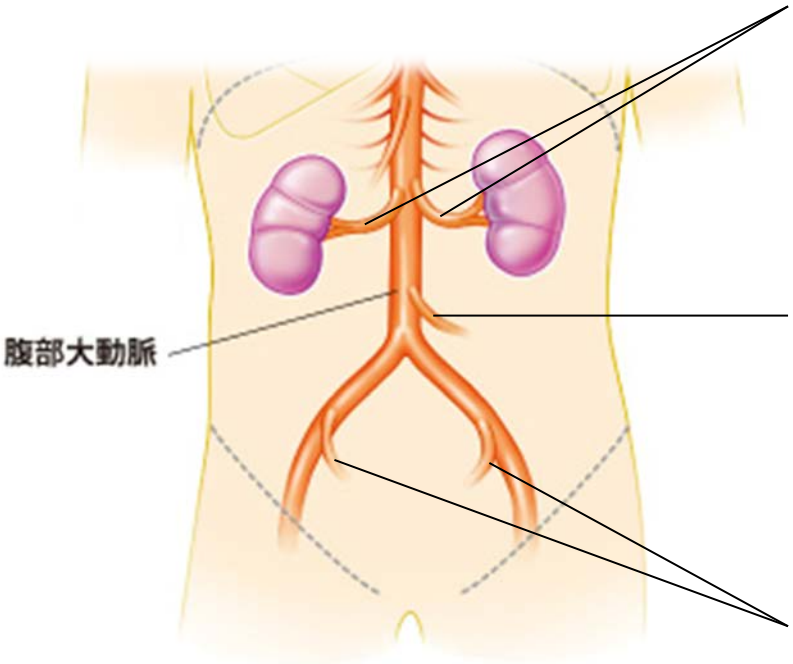

腎動脈 ✖

つぶせない血管

離れていることが多い

下腸間膜動脈 ◎

つぶせる血管

腸の血液は上腸間膜動脈でカバーされる

内腸骨動脈 ◎

つぶせる血管

殿筋跛行やインポテンツになることあり

TEVARにおける重要分枝

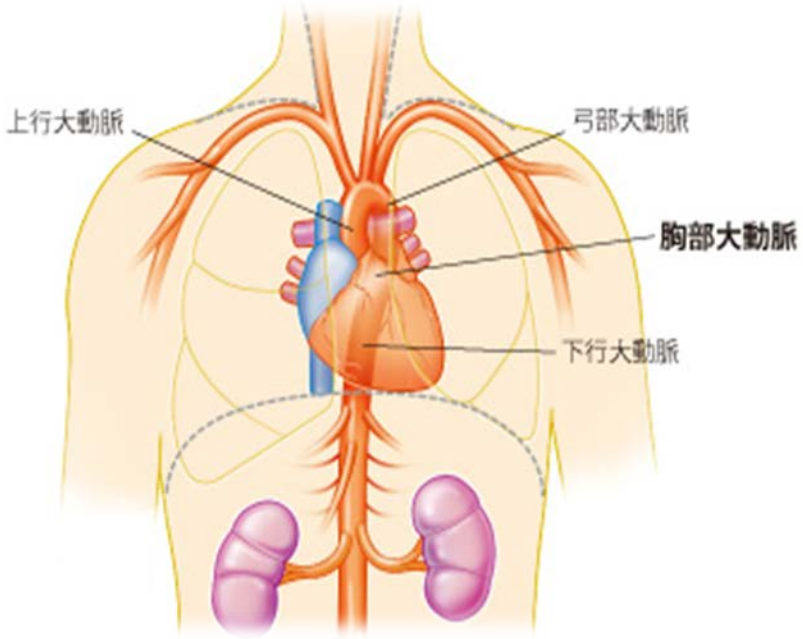

冠動脈 ✖

腕頭動脈 ✖

左総頸動脈 ✖

左鎖骨下動脈 ▲

まれに脳梗塞になるひとがいる

脳内の血管のつながりによる

腹腔動脈 ▲

まれに消化管虚血になるひとがいる

上腸間膜動脈とのつながりによる

上腸間膜動脈 ✖

腎動脈 ✖

分枝はどうするのか？

日本で売っているものでなんとかする方法

デブランチ法
チムニーグラフト法

日本で売ってないものを輸入してつかう方法

穴あきグラフト（＝フェネ）
枝付きグラフト（＝ブランチ）

デブランチとは？

de　＋　branch　＝　別の経路でバイパスする

切り離す　　分枝を

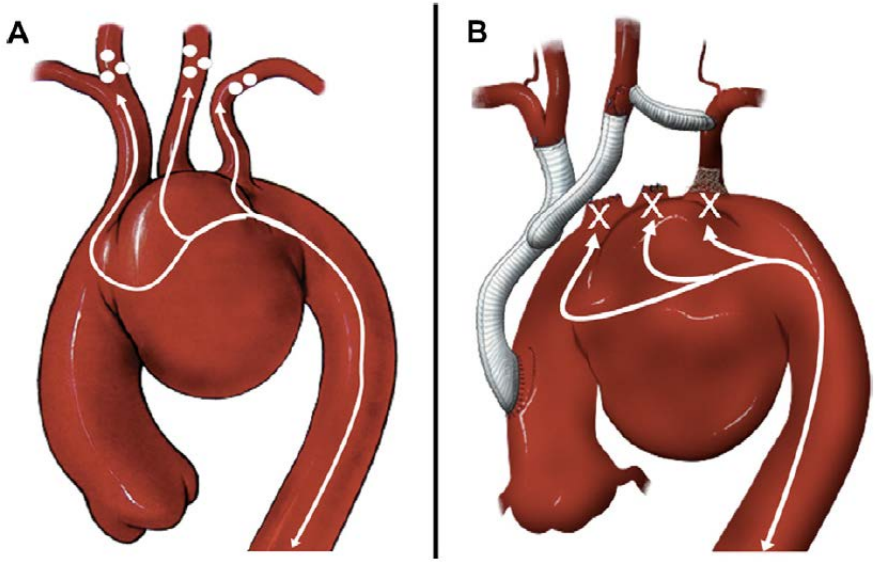

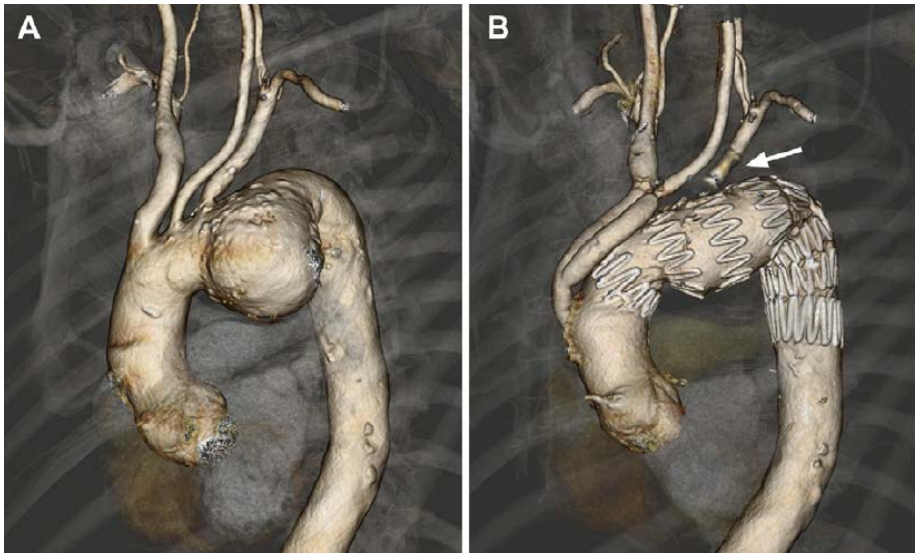

弓部のデブランチ

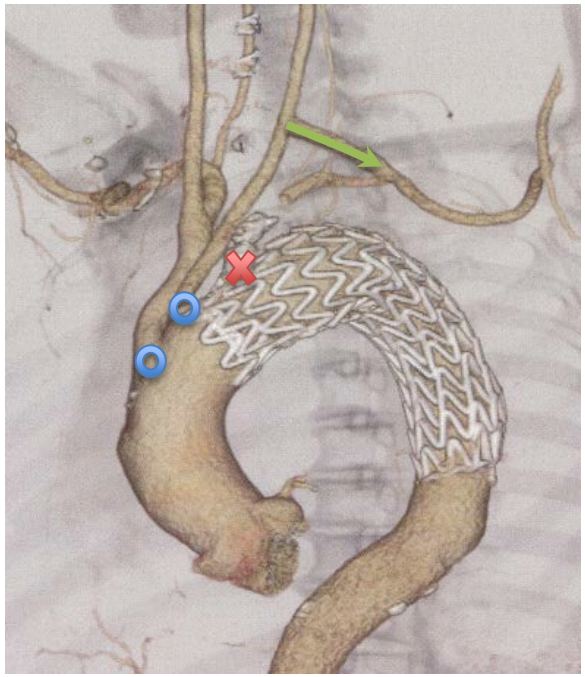

1 デブランチ

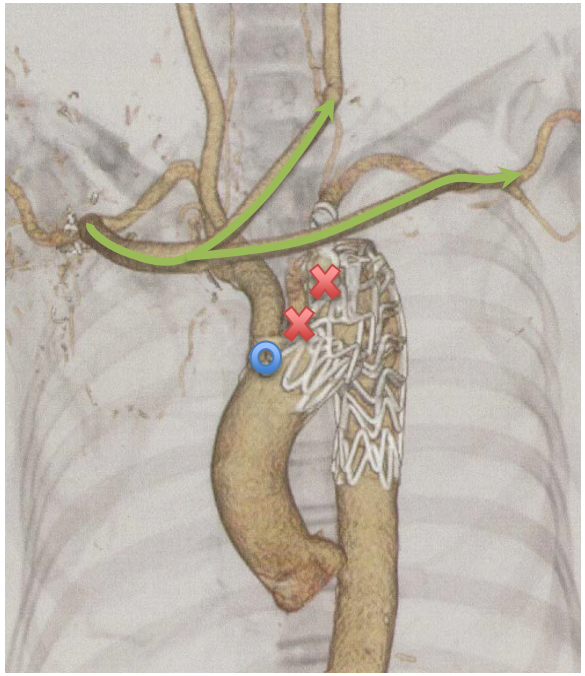

2 デブランチ

3 デブランチ

胸腹部のデブランチ

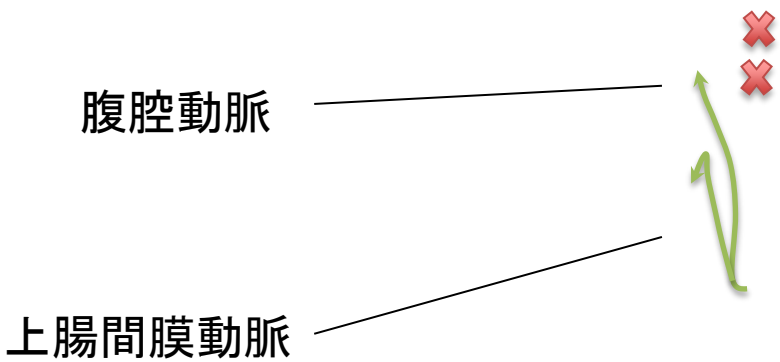

チムニーグラフト法

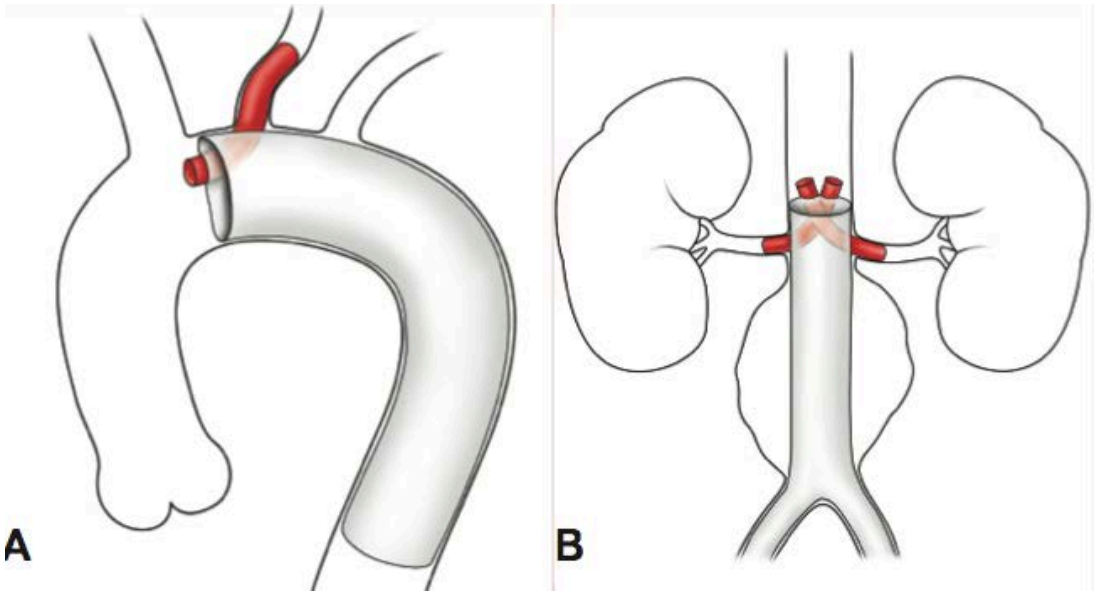

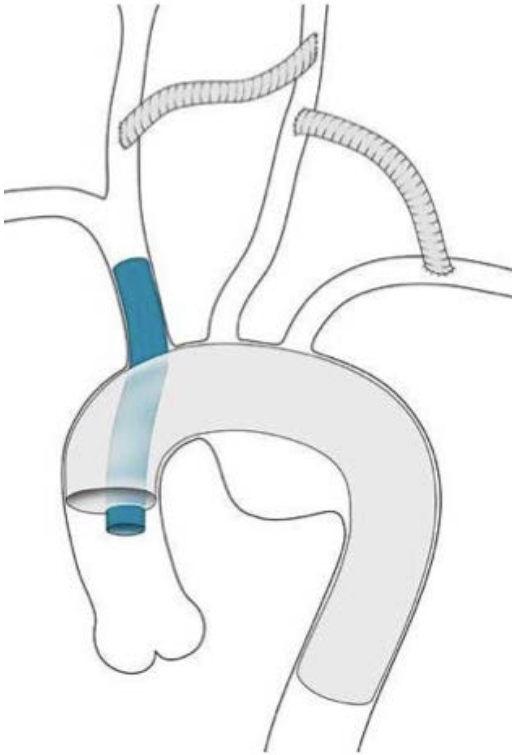

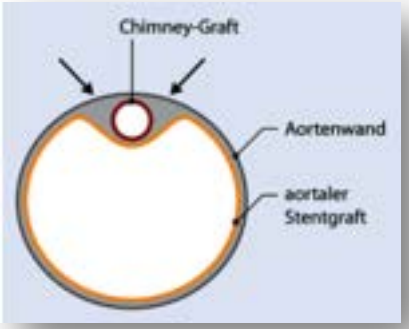

ブランチ or フェネ

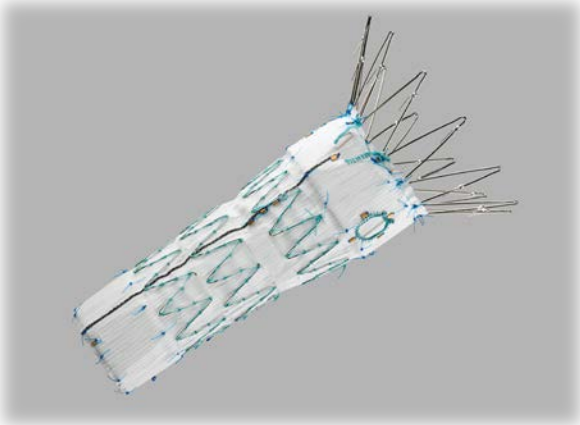

弓部のブランチ

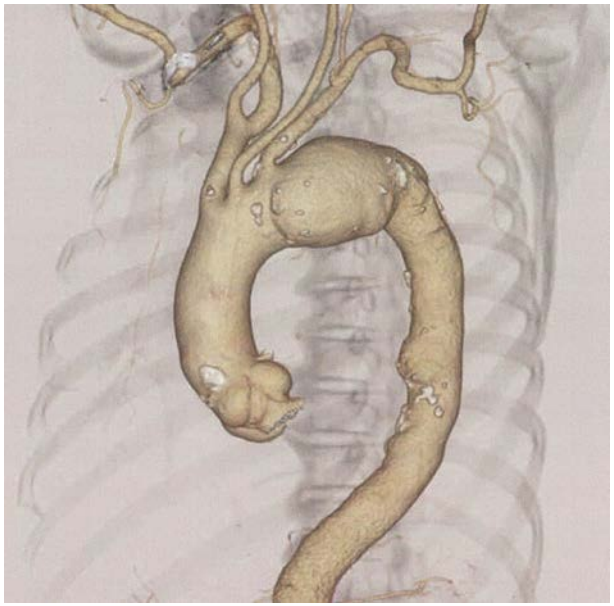

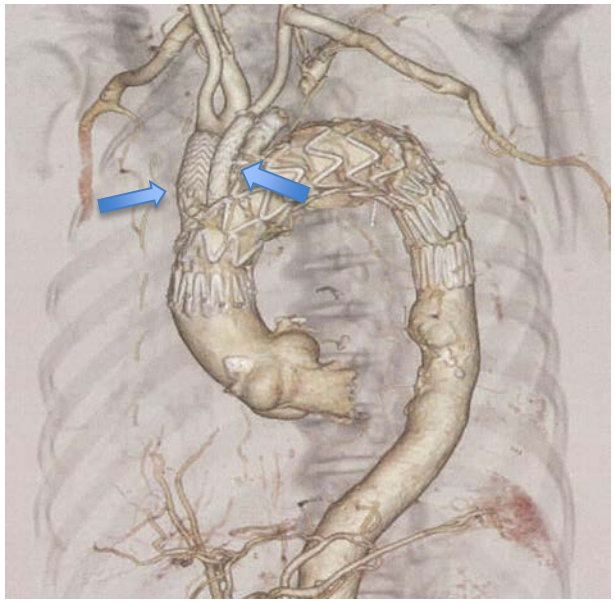



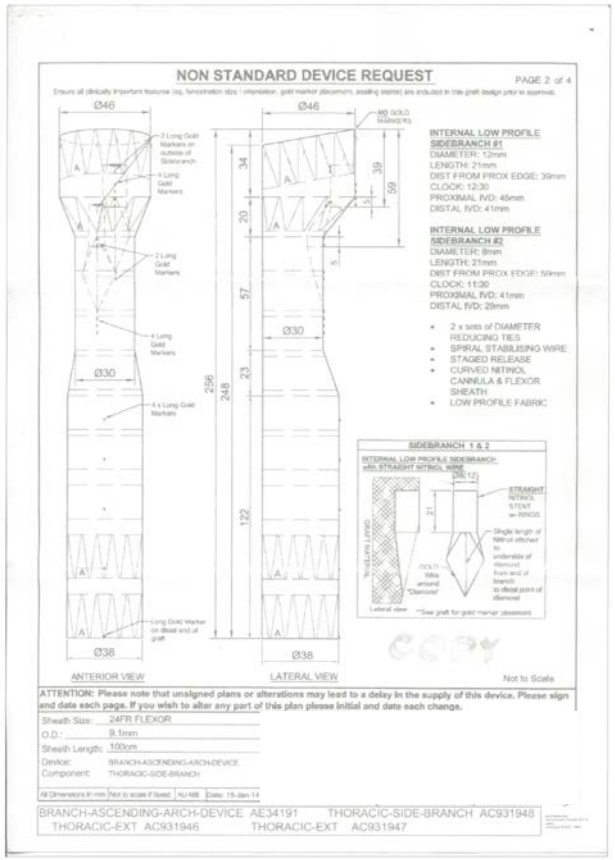

NON STANDARD DEVICE REQUEST

PAGE 2 of 4

Ensure all clinically important features (eg, fenestration size / orientation, gold marker placement, sealing stents) are included in the graft design prior to approval.

Ø46 — Ø30 — Ø38 — ANTERIOR VIEW

Ø46 — Ø30 — Ø38 — LATERAL VIEW

NO GOLD MARKERS

2 Long Gold Markers on outside of Sidebranch

4 Long Gold Markers

2 Long Gold Markers

4 Long Gold Markers

4 x Long Gold Markers

Long Gold Marker on distal end of graft

34 20 57 23 122 256 248 39 59

INTERNAL LOW PROFILE SIDEBRANCH #1
DIAMETER: 12mm
LENGTH: 21mm
DIST FROM PROX EDGE: 39mm
CLOCK: 12:30
PROXIMAL IVD: 45mm
DISTAL IVD: 41mm

INTERNAL LOW PROFILE SIDEBRANCH #2
DIAMETER: 8mm
LENGTH: 21mm
DIST FROM PROX EDGE: 59mm
CLOCK: 11:30
PROXIMAL IVD: 41mm
DISTAL IVD: 29mm

- 2 x sets of DIAMETER REDUCING TIES
- SPIRAL STABILISING WIRE
- STAGED RELEASE
- CURVED NITINOL CANNULA & FLEXOR SHEATH
- LOW PROFILE FABRIC

SIDEBRANCH 1 & 2

INTERNAL LOW PROFILE SIDEBRANCH with STRAIGHT NITINOL WIRE

(Ø12) 21

STRAIGHT NITINOL STENT w/ RINGS

Single length of NiTinol attached to underside of diamond from end of branch to distal point of diamond

GOLD Wire around "Diamond"

Lateral view

*See graft for gold marker placement

Not to Scale

ATTENTION: Please note that unsigned plans or alterations may lead to a delay in the supply of this device. Please sign and date each page. If you wish to alter any part of this plan please initial and date each change.

Sheath Size: 24FR FLEXOR
O.D.: 9.1mm
Sheath Length: 100cm
Device: BRANCH-ASCENDING-ARCH-DEVICE
Component: THORACIC-SIDE-BRANCH

All Dimensions in mm | Not to scale if faxed | AU-NB | Date: 15-Jan-14

BRANCH-ASCENDING-ARCH-DEVICE AE34191 THORACIC-SIDE-BRANCH AC931948
THORACIC-EXT AC931946 THORACIC-EXT AC931947

胸腹部のフェネ

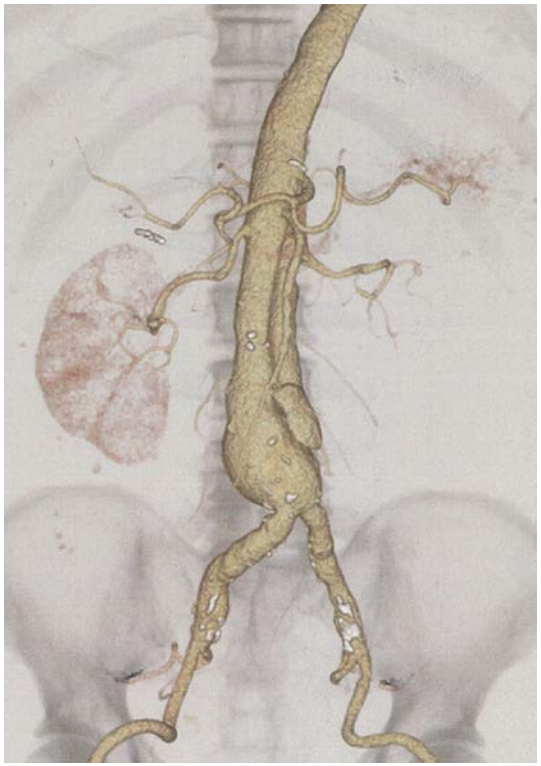

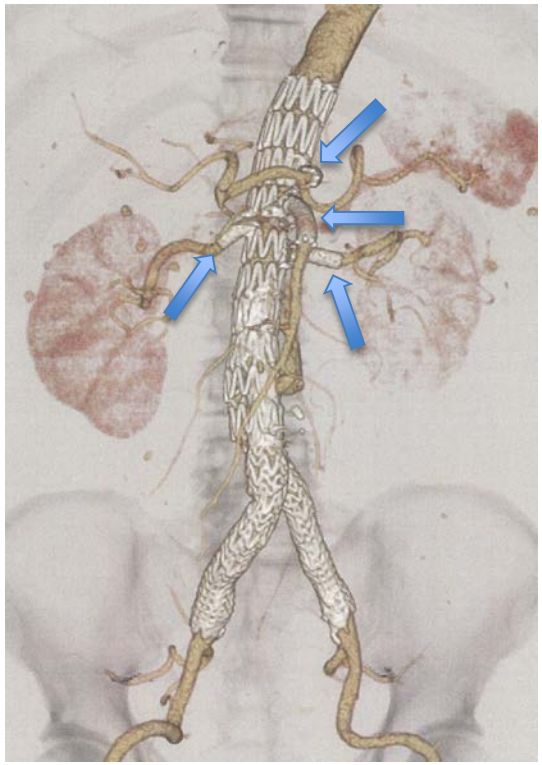



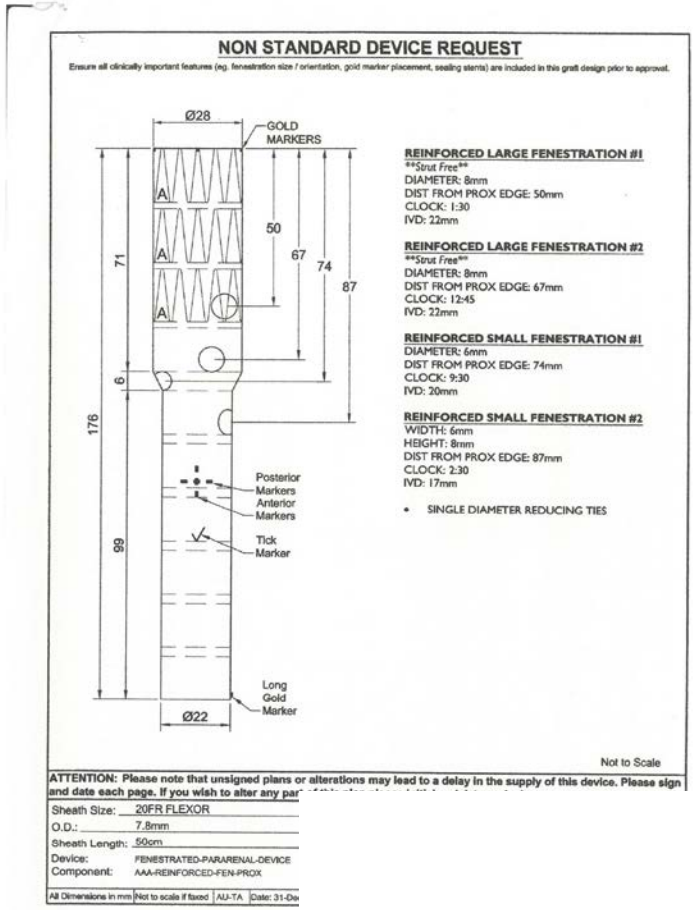

NON STANDARD DEVICE REQUEST

Ensure all clinically important features (eg. fenestration size / orientation, gold marker placement, sealing stents) are included in this graft design prior to approval.

Ø28
GOLD MARKERS
A
A
A
50
67
74
87
71
6
176
99
Posterior Markers
Anterior Markers
Tick Marker
Long Gold Marker
Ø22

REINFORCED LARGE FENESTRATION #1
Strut Free
DIAMETER: 8mm
DIST FROM PROX EDGE: 50mm
CLOCK: 1:30
IVD: 22mm

REINFORCED LARGE FENESTRATION #2
Strut Free
DIAMETER: 8mm
DIST FROM PROX EDGE: 67mm
CLOCK: 12:45
IVD: 22mm

REINFORCED SMALL FENESTRATION #1
DIAMETER: 6mm
DIST FROM PROX EDGE: 74mm
CLOCK: 9:30
IVD: 20mm

REINFORCED SMALL FENESTRATION #2
WIDTH: 6mm
HEIGHT: 8mm
DIST FROM PROX EDGE: 87mm
CLOCK: 2:30
IVD: 17mm

- SINGLE DIAMETER REDUCING TIES

Not to Scale

ATTENTION: Please note that unsigned plans or alterations may lead to a delay in the supply of this device. Please sign and date each page. If you wish to alter any par

Sheath Size: 20FR FLEXOR
O.D.: 7.8mm
Sheath Length: 50cm
Device: FENESTRATED-PARARENAL-DEVICE
Component: AAA-REINFORCED-FEN-PROX

All Dimensions in mm | Not to scale if faxed | AU-TA | Date: 31-De

TEVARの今後

ほとんどが
急性A型解離

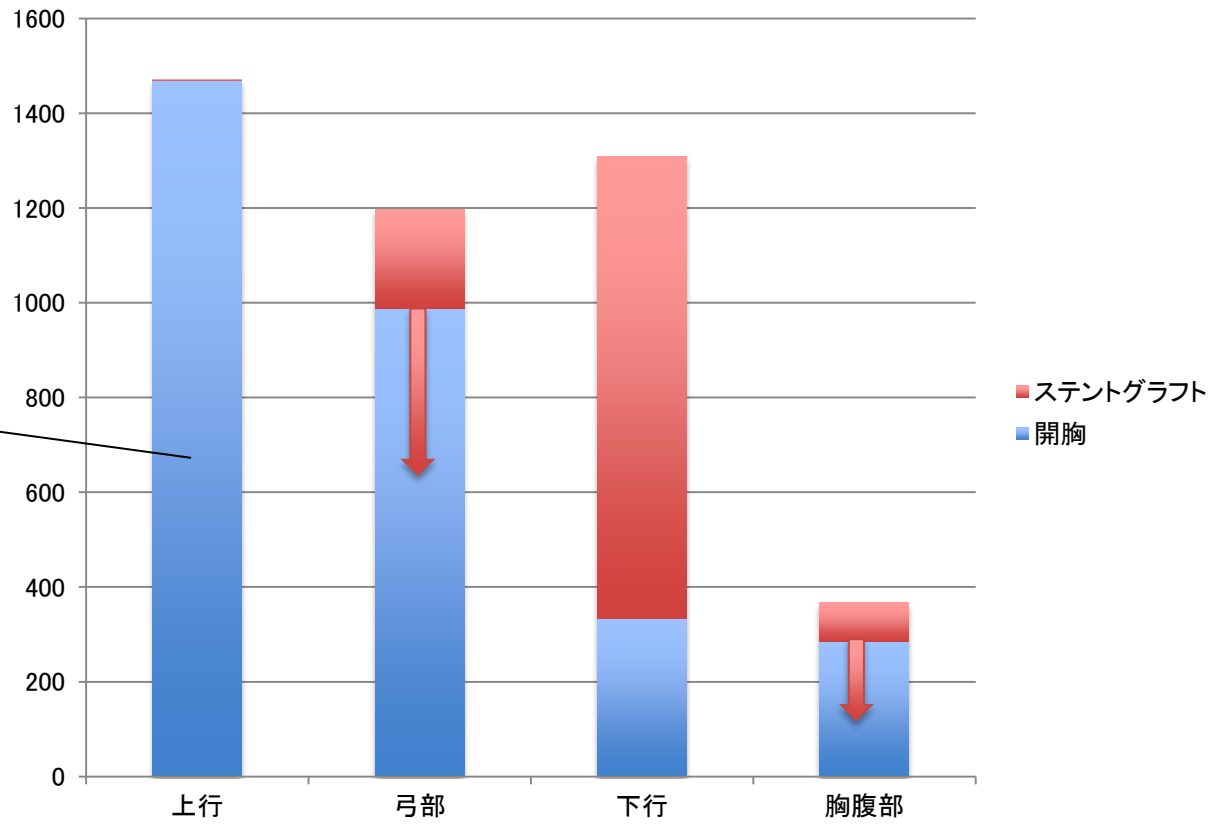

デバイス と 合併症 が課題

ステントグラフトの合併症

脳梗塞（おもに弓部の合併症）

開胸手術　＜　ステントグラフト

➢　ステントグラフト治療の今後の課題

脊髄虚血（おもに胸腹部の合併症）

開胸手術　＞　ステントグラフト

➢　ステントグラフトの普及で増加する可能性

両下肢麻痺はなぜ起こる？

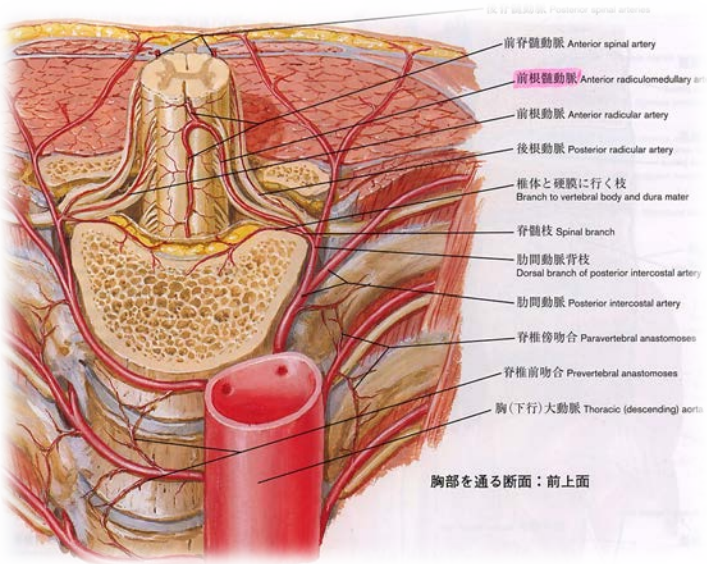

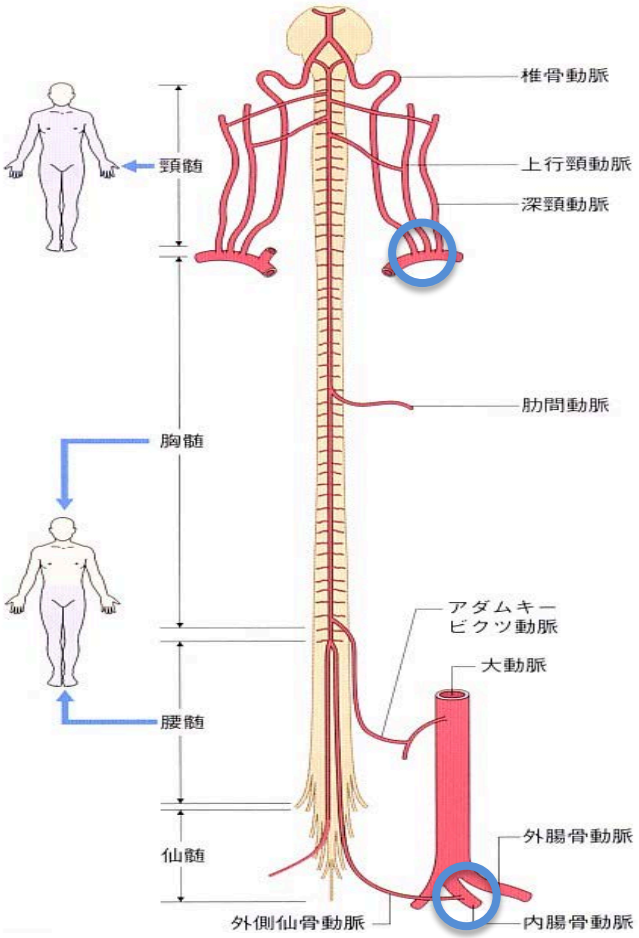

肋間動脈？

アダムキュービッツ動脈？

手術中の低血圧？

広範囲なネットワークと周術期の血圧維持が重要

今日のおはなし

- ✓ ステントグラフトとは？
- ✓ 腹部大動脈瘤のステントグラフト治療
- ✓ 胸部大動脈瘤のステントグラフト治療
- ✓ 症例提示

症例1

- ７６歳男性
- 現病歴

２０１４年９月７日、農作業時に突然の左背部痛出現。当院に救急搬送、来院時ショック状態であり、急性大動脈解離による胸腔内穿破にて緊急手術となる。

術前CT

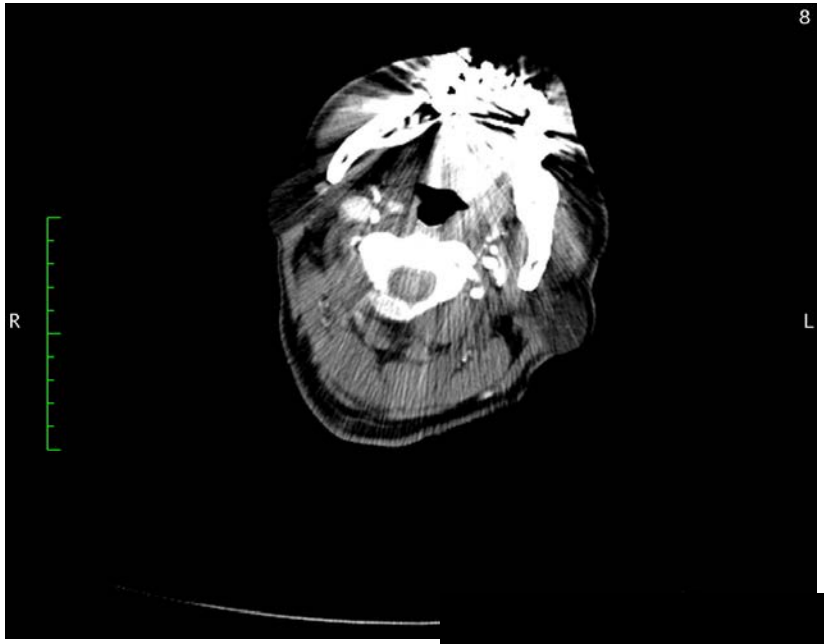
8
R
L

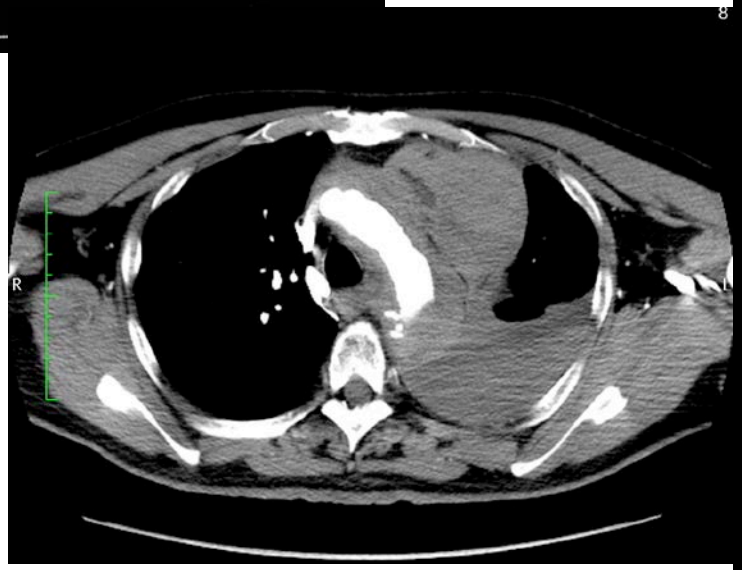
8
R

STND/+
114
R
A
L
P
114/5
No VOI
kv 120
mA Mod.
Zoom:120% Angle: 0
Im:5/25
2014/09/07 8:10:16
Uncompressed
Made In OsiriX

術後CT

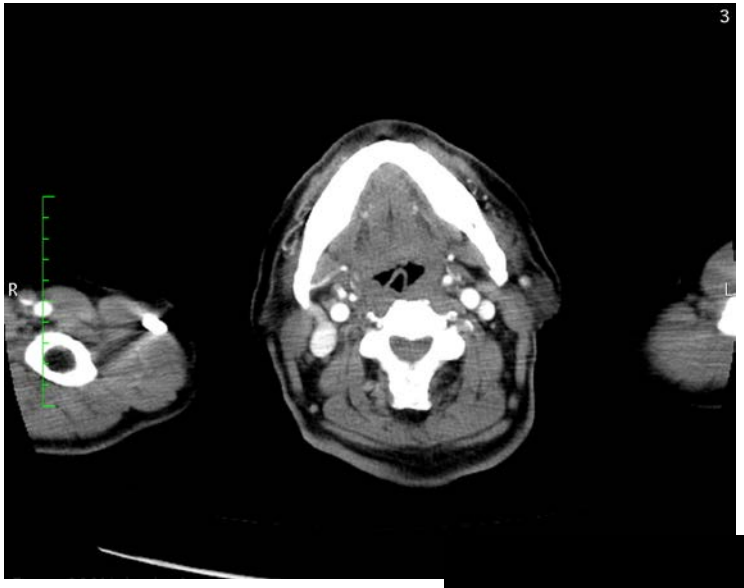

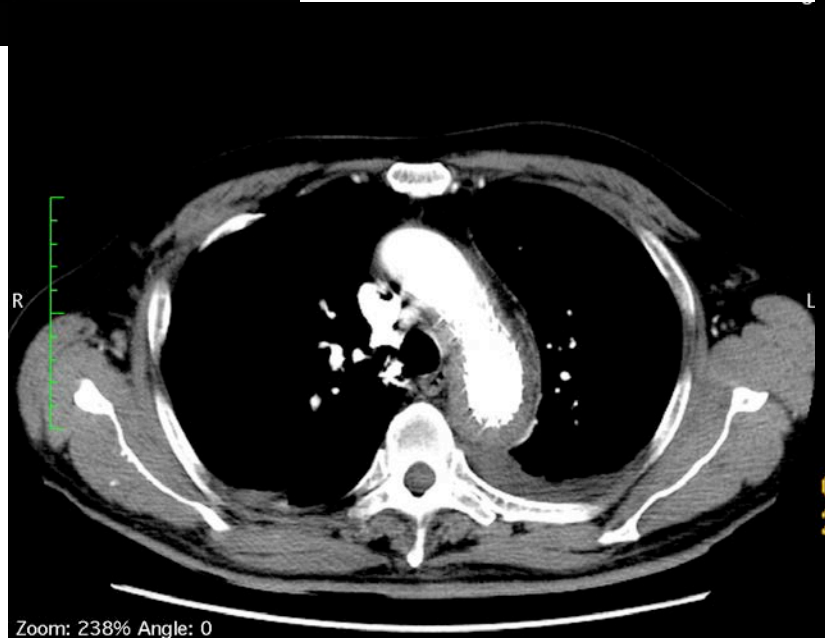

症例2

- ６６歳男性
- 現病歴

２０１４年９月７日、トラクター運転中に田んぼに転落。救急搬送され、来院時はショック状態であり、外傷性胸部大動脈損傷、肝損傷、右血胸、右多発肋骨骨折、多発骨盤骨折にて緊急手術となる。

術前CT

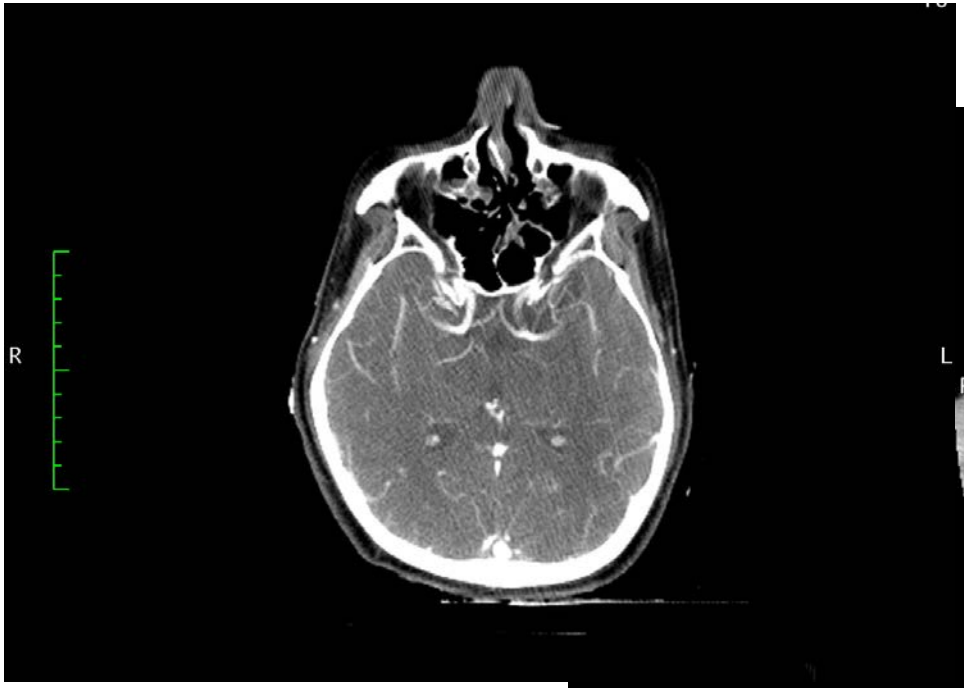
R

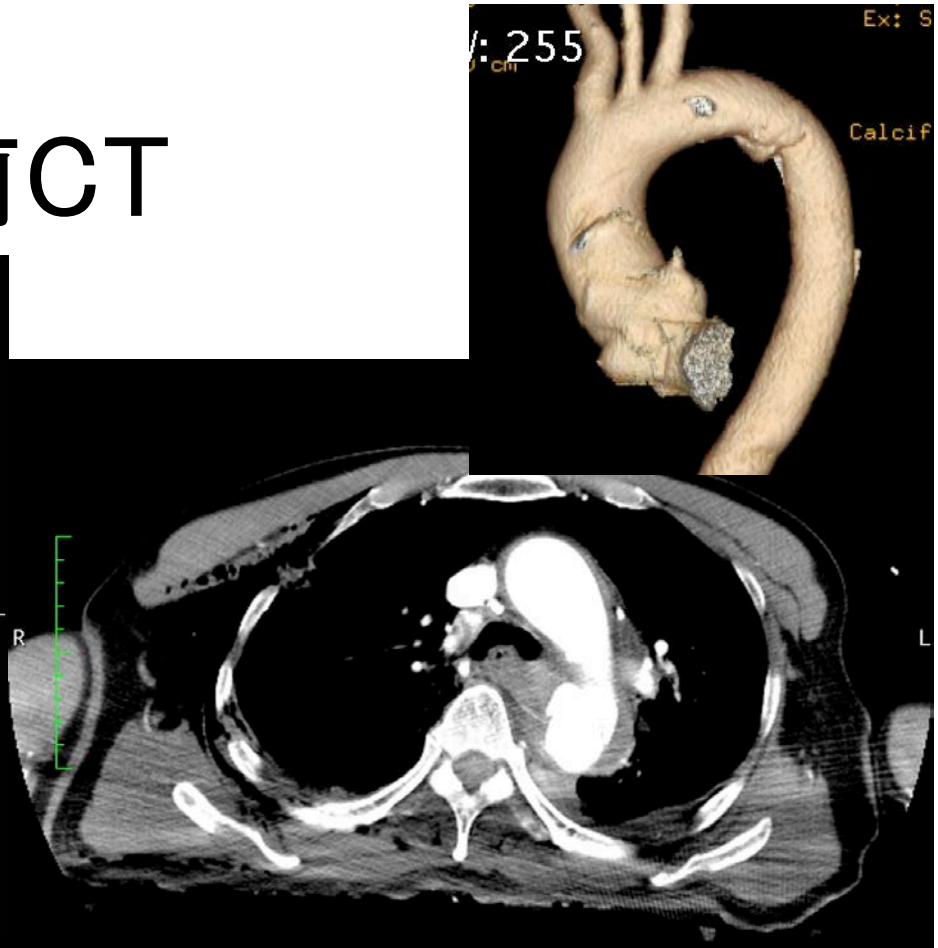
Ex: S
Calcif
L
R
L

R
L

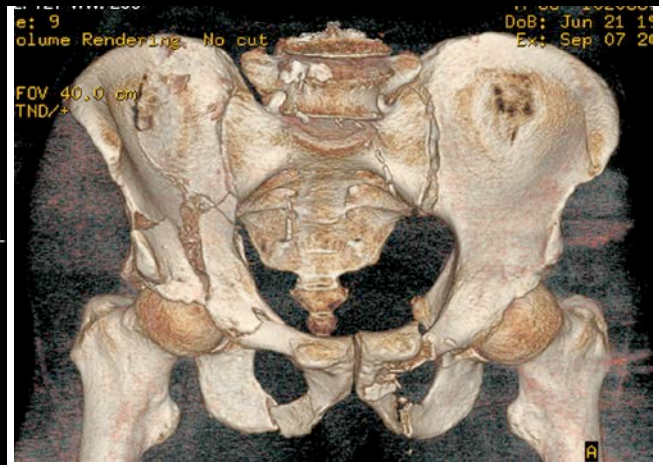
DoB: Jun 21 1
Ex: Sep 07 2
olume Rendering No cut
FOV 40.0 cm
TND/+

術後CT

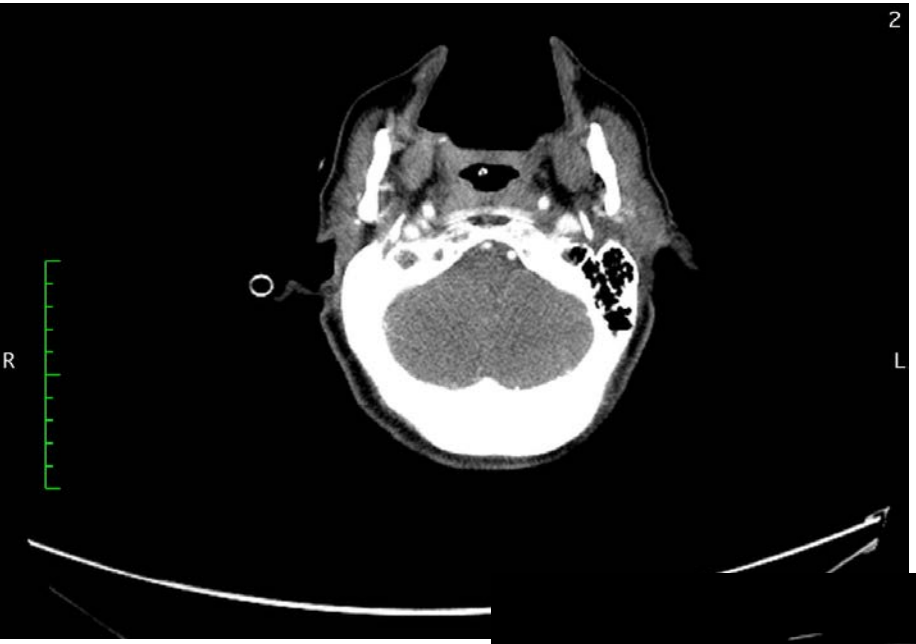

ご静聴ありがとうございました